

ORIGINAL ARTICLE

Cerebroprotective properties of recombinant interleukin-1 receptor – an experimental study

Cerebroprotektivní vlastnosti rekombinantního antagonisty receptoru pro interleukin-1 – experimentální studie

Katherine Shchokina • Vira Ulanova • Svitlana Drogovoz

Received November 18, 2021 / Accepted February 4, 2021

Summary

Optimization of therapy of cerebrovascular disorders (CVD) is one of the most critical health problems. The current treatment regimen of CVD turns out to be often insufficient. Search for new drugs with cerebroprotective and antihypoxic properties is an essential task of modern medicine and pharmacy. Attention to cytokine mechanisms of ischemic brain damage in clinics and experimental research has been increased recently. Interleukin-1 (IL-1) receptor blockade is a perspective way of cerebroprotection that requires a more profound study of its mechanisms. The article contains the results of a study of cerebroprotective and antihypoxic properties of the recombinant IL-1 antagonist raleukin on a model of bilateral carotid occlusion in rats. Recombinant receptor antagonist IL-1 raleukin (15 mg/kg) did not affect basal blood flow in the internal carotid artery of intact group animals. Still, it prevented its decrease approximately three times in case of occlusion of both common carotid arteries followed by reperfusion. Indicators of the cerebroprotective effect of studied medication were reducing the acidotic blood shift flowing from the brain of animals with irreversible bilateral carotid occlusion, neuronal degradation, and weakening.

Key words: cerebral ischemia • interleukin-1 • raleukin • bilateral carotid occlusion • neuron-specific enolase

Souhrn

Optimalizace terapie cerebrovaskulárních poruch (CVD) je jedním z nejvýznamnějších zdravotních problémů.

Současný léčebný režim CVD se často ukazuje jako nedostatečný. Hledání nových léků s cerebroprotektivními a antihypoxickými vlastnostmi je základním úkolem moderní medicíny a farmacie. Cytokinovým mechanismům ischemického poškození mozku se v poslední věnována zvyšující se pozornost v rámci klinické praxe i experimentálního výzkumu. Blokáda receptoru interleukin-1 (IL-1) je perspektivní způsob cerebroprotektce, který vyžaduje hlubší studium jejích mechanismů. Článek přináší výsledky studie cerebroprotektivních a antihypoxických vlastností rekombinantního antagonisty IL-1 raleukinu na modelu bilaterální karotické okluze u potkanů. Antagonista rekombinantního receptoru IL-1 raleukin (15 mg/kg) neovlivnil bazální průtok krve v arteria carotis interna intaktních skupin zvířat. Zabránil však jeho poklesu přibližně trojnásobně v případě uzávěru obou společných karotid s následnou reperfuze. Indikátory cerebroprotektivního účinku studovaného léku byly snížení acidotického posunu krve proudící z mozku u zvířat s ireverzibilní bilaterální karotidovou okluzí, neuronální degradaci a oslabením.

Klíčová slova: cerebrální ischemie • interleukin-1 • raleukin • bilaterální karotická okluze • neuron-specifická enoláza

Introduction

Optimization of therapy of cerebrovascular disorders (CVD) is one of the most important health problems¹⁾. The current treatment regimen of CVD turns out to be often insufficient²⁾. Search for new drugs with cerebroprotective and anti-hypoxic properties is an essential task of modern medicine and pharmacy.

Attention to cytokine mechanisms of ischemic brain damage in the clinic and experiment has recently increased. Interleukin-1 (IL-1) exhibits a rapid manifestation which causes leukocytic infiltration and neurotoxicity (apoptosis)^{3, 4)}. There is strong evidence of interrelation between receptor antagonists IL-1 and correction of cerebrovascular disorders^{5, 6)}.

Katherine Shchokina (✉) • V. Ulanova • S. Drogovoz
National University of Pharmacy, Kharkiv, Ukraine
Department of Pharmacology and Pharmacotherapy of the National University of Pharmacy
Pushkinska St. 53, 61002 Kharkiv, Ukraine
e-mail: acya@ukr.net

Early research findings showed that raleukin, the original recombinant antagonist of IL-1 receptors of Highly Pure Biochemicals (St. Petersburg, Russia), increases survival rate in rats with bilateral carotid occlusion (BCO), reduces symptoms of cerebrocardial syndrome, strengthens resistance to hypoxia, and decreases the level of toxic and traumatic brain injury^{7–9}. Thus, IL-1 receptor blockade is a perspective way of cerebroprotection that requires a more profound study of its mechanisms. According to the data shown, it is supposed not to be limited to improving energy metabolism in the brain^{10, 11}. Raleukin effect on cerebral blood flow in normal and CVD at cerebral ischemia that induces acid-base shift and level of neuron destruction have not been investigated thoroughly.

Experimental part

The experiments were performed on white male rats of the Wistar line, 200–220 grams of weight each. Experimental animals were kept under sanitary and hygienic standards in compliance with the principles of Directive 2010/63/EU of the European Parliament and of the Council «On the protection of animals used for scientific purposes» (Brussels, 2010), the Law of Ukraine «On Animal Protection» from brutal driving № 3477-IV of 21.02.2006 (as amended) and the Order of the Ministry of Education and Science of Ukraine About the statement of the Order of carrying out by scientific institutions of experiments, experiments on animals № 249 from 01.03.2012, as evidenced by the conclusion of the commission on bioethics of the National University of Pharmacy. Procedures that caused pain or suffering of animals were performed under anesthesia (xylazine i/m 5 mg/kg, thiopental intraperitoneally 40–70 mg/kg).

Raleukin (St. Petersburg Research Institute OCHBP) used in a conventionally-effective dose of 15 mg/kg^{2, 12}, administered daily subcutaneously for three days, last 30–40 minutes before CVD modeling. Cardiovascular disorder of ischemic type in the forebrain was reproduced by BCO¹³.

In the first series of experiments, the dynamic of cerebral blood flow in ischemic conditions was followed by reperfusion determination. For this action, vessels were dissected, provisional ligatures were summed, and a superimposed ultrasonic flowmeter sensor 106 T (Transonic Systems Inc., USA) was applied on the left internal carotid artery. After hemodynamic stabilization, basal blood flow was measured, the right common carotid artery was ligated, and a miniature clamp was applied on the left common carotid artery for 40 minutes, which stopped cerebral blood flow from the carotid completely. After 40 min, the clip was removed, and blood flow in the left internal carotid artery was measured in the dynamic of reperfusion for 60 min. Vinpocetine was selected as a reference drug (Cavinton, Gedeon Richter, Hungary)^{14, 15} administered in a dose of 5 mg/kg i.p. in the same way as raleukin.

Raleukin was administered in rats with irreversible BCO at the above-mentioned scheme in the second series of experiments. After 1-day indices, acid-base balance was measured by an analyzer «Radiometer» (Denmark). The blood (0.2–0.3 mL) was collected from the sigmoid sinus into a heparinized syringe and stored at 3–4 °C no more than 15 minutes before analysis. The content of neuron-specific enolase (NSE) in blood was measured by ELISA using a kit NSE EIA KIT (DAI, USA) «Hipson» firm device (Czech Republic). The release of NSE (2-phospho-D glycerate hydrolyse, EC 4.2.1.11) from neurons into the spinal CSF and blood is an important marker of neural tissue damage degree¹⁶. NSE level in serum of patients with CVD correlates with the volume of cerebral infarction¹⁷.

At the end of the experiment, microscopic examinations were performed. The functional state of neurons was analyzed in 3–5 layers of the cortex. In these sections, the number of neuronal and glial cells was counted on a standard area in 5 replicates (approx. 7, lens 40), and the glioneuronal index was determined. The micro-preparations were examined under a Mikros 400 microscope, and the images were microphotographed with a Nikon Cool Pix 4500 digital camera. The photographs were processed on a computer using Nikon View 5 software.

The obtained data of inner group differences were evaluated by pairwise Wilcoxon test, inner group differences by the Student t-criterion, absence of a normal distribution by White Brown, evaluation in an alternative form by angular Fischer transformation.

Results and discussion

Neither raleukin nor vinpocetine affected basal blood flow in the internal carotid artery. Indicators in corresponding groups had no significant differences from those in the control one with a 6–7% (Table 1). Brain reperfusion in test groups after 40 min of ischemia varied considerably. In the control group, the flow rate in the internal carotid artery decreased on average by more than 50% relative to the basal level. After raleukin and vinpocetine administration, blood flow was restored significantly, reduction of ischemia was 18–19% and 9–11%, respectively ($p < 0,001$ compared to the control group). The decrease in the vinpocetine group was minimal, but the absolute blood flow in raleukin and vinpocetine groups had no significant differences (Table 1).

Thus, blockade of IL-1 receptors in CVD influences the state of blood vessels, enhancing blood supply to the brain after removing the vascular occlusion approximately at the vinpocetine level. This cerebroprotection mechanism in cerebral ischemia can be considered to be a primary one because violation of energy metabolism is caused by ischemia. Along with this, raleukin increases resistance to brain hypoxia of nonischemic origin^{18, 19}.

Table 1. *Raleukin effect on blood flow in the internal carotid artery in ischemia-reperfusion in the rat brain, $M \pm SD$*

Observation time	Control (n = 7)		Raleukin, 15 mg/kg (n = 7)		Vinpocetine, 5 mg/kg (n = 7)	
	ml/min	change%	ml/min	change%	ml/min	change%
The initial state						
first measurement	6.80 \pm 0.25	–	6.34 \pm 0.15	–	6.46 \pm 0.22	–
5 min	6.77 \pm 0.22	–	6.39 \pm 0.15	–	6.46 \pm 0.17	–
10 min	6.83 \pm 0.22	basal (100%)	6.43 \pm 0.17	basal (100%)	6.36 \pm 0.22	basal (100%)
40 min ischemia followed by reperfusion						
5 min	3.33 \pm 0.11*	–51.2 \pm 0.7	5.26 \pm 0.17**	–17.7 \pm 0.6 [#]	5.81 \pm 0.27*	–8.7 \pm 1.68 ^{#^}
10 min	3.21 \pm 0.08*	–52.8 \pm 0.8	5.23 \pm 0.14**	–18.1 \pm 0.9 [#]	5.67 \pm 0.26*	–11.0 \pm 1.33 ^{#^}
20 min	3.20 \pm 0.12*	–53.0 \pm 1.4	5.21 \pm 0.13**	–18.3 \pm 1.2 [#]	5.67 \pm 0.21*	–10.9 \pm 1.48 ^{#^}
30 min	3.11 \pm 0.07*	–53.6 \pm 1.2	5.23 \pm 0.15**	–18.1 \pm 0.8 [#]	5.69 \pm 0.20*	–10.6 \pm 1.70 ^{#^}
40 min	3.10 \pm 0.11*	–54.2 \pm 0.9	5.19 \pm 0.18**	–18.8 \pm 0.9 [#]	5.72 \pm 0.22*	–9.9 \pm 1.26 ^{#^}
60 min	3.19 \pm 0.11*	–53.3 \pm 0.4	5.16 \pm 0.18**	–19.2 \pm 0.8 [#]	5.64 \pm 0.26*	–11.4 \pm 1.90 ^{#^}

Statistically significant differences ($p < 0.05$).

n – the number of animals in the group

* with the initial state within the group (for pairwise Wilcoxon test)

with simultaneous indication of the control group

^ with a synchronous indicator of the group receiving raleukin

Table 2. *Effect on raleukin indicators of acid-base balance in venous blood after one day of bilateral carotid occlusion in rats, $M \pm SD$*

Indicators	Control, n = 6	Control Pathology (BCO), n = 6	Raleukin, 15 mg/kg + BCO, n = 5	Vinpocetine 5 mg/kg + BCO, n = 6
pH	7.23 \pm 0.001	6.80 \pm 0.035*	7.12 \pm 0.022**	7.15 \pm 0.008**
pCO ₂ , mmHg. Art.	74.7 \pm 0.87	89.3 \pm 1.23*	70.6 \pm 1.51**	74.1 \pm 1.45 [#]
pO ₂ , mmHg. Art.	76.7 \pm 0.81	56.3 \pm 1.77*	67.8 \pm 2.30**	67.5 \pm 3.06**
Hb, g/dl	11.0 \pm 0.32	8.65 \pm 0.44*	11.4 \pm 0.34 [#]	10.8 \pm 0.30 [#]
AB, mmol/l	24.5 \pm 0.68	12.2 \pm 0.65*	21.1 \pm 0.52**	20.8 \pm 0.48**
BBS, mmol/l	25.6 \pm 1.23	12.4 \pm 0.32*	20.0 \pm 0.79**	18.3 \pm 0.48**
BE, mmol/l	1.88 \pm 0.11	–3.03 \pm 0.21*	0.60 \pm 0.55**	0.33 \pm 0.19**
SB, mmol/l	25.7 \pm 0.58	12.7 \pm 0.53*	20.5 \pm 0.73**	20.3 \pm 0.56*

Statistically significant differences ($p < 0.05$).

n – the number of animals in the group, that pCO₂, pO₂ – partial pressure of CO₂ and O₂, Hb – hemoglobin, AB – actual bicarbonate, BE – buffer base deficiency, BBS – the sum of the of buffer bases, SB – standard bicarbonate

* with a group of control

a group of control pathology

Blockade of IL-1 receptors as evidenced by measurement of cerebral blood flow (Table 1) significantly reduced the degree of cerebral ischemia in the acute phase.

Cerebral ischemia provoked severe metabolic acidosis. In the control pathology group, after 1 day of BCO pH decreased and CO₂ partial pressure increased in venous blood flowing from the brain (Table 2). A decrease in hemoglobin and oxygen saturation of blood, a significant shortage of buffer base deficiency catches attention in this case. These results do not align with the data of moderate respiratory alkalosis due to hyperventilation in rats with BCO (15, 20). Reasons for differences are likely to be that in the mentioned study, the acid-base balance was measured in arterial blood 35 minutes after BCO, while we defined it in the venous

blood of the sigmoid sinus in 1 day after BCO when the mechanism of compensatory hyperventilation was exhausted.

Raleukin took away acid-base balance disorders at vinpocetine level (Table 2). It agrees with its property to reduce lactate accumulation in experimental cerebral ischemia^{1, 20}.

According to Table 3, in rats of the control pathology group after 1 day, BCO NSE activity increased by 11.2 times on average –from 0.61 ng/ml to 6.86 ng/ml ($p < 0.001$), strongly indicating neurons destruction. After raleukin administration this index increased only by 3.43 ng/ml ($p < 0.001$). Thus, raleukin reduced the destruction of neurons with slight concession to Vinpocetine I (producing an effect close to Vinpocetine with the average activity of 2.34 ng/mL).

Table 3. Influence of raleukin on neuron enolase activity in the blood after one day of bilateral carotid occlusion in rats, $M \pm SD$

Number	Group	Number of animals in group	Neuron specific enolase		p
			ng/ml	%	
1	Control	8	0.61 ± 0.02	100	–
2	Control pathology	7	6.86 ± 0.21	1125	$p_{2-1} < 0.001$
3	Raleukin, 15 mg/kg	7	3.43 ± 0.10	562	$p_{3-1} < 0.001$ $p_{3-2} < 0.001$
4	Vinpocetin, 5 mg/kg	7	2.34 ± 0.08	384	$p_{4-1} < 0.001$ $p_{4-2} < 0.001$ $p_{4-3} < 0.001$

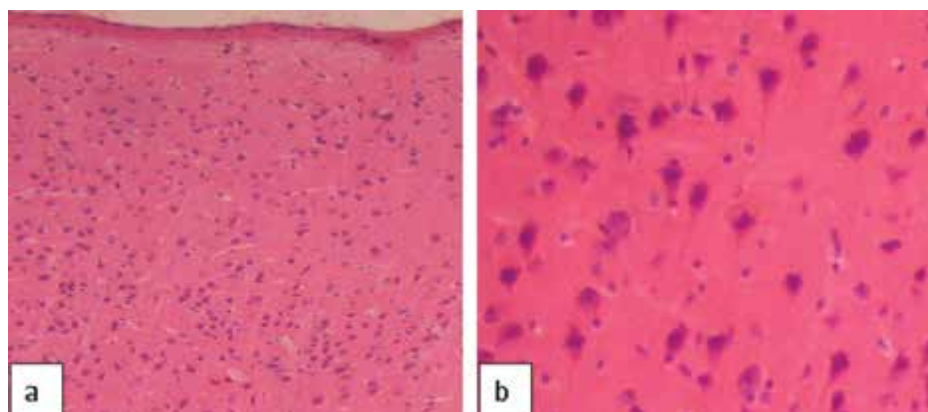


Fig. 1. Area of the cerebral hemisphere of the pseudo-operated rat 24 hours after the intervention: a – normal cytoarchitectonics ($\times 100$); b – normal neuropil density, ratio of neurons and glial cells ($\times 200$) (hematoxylin-eosin)

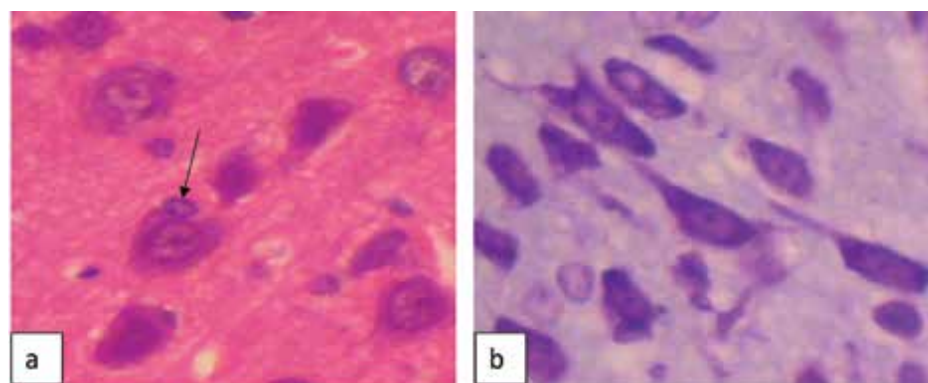


Fig. 2. A section of the cerebral hemisphere of a pseudo-operated rat a day after the intervention. It can be seen: a – a satellite cell closely adjoining the perikaryon bay (arrow); b – normal neurons with a tigroid uniformly distributed in the neuropil (a – hematoxylin-eosin, $\times 400$; b – thionine according to Nissl, $\times 400$)

The morphological features of the sensorimotor cortex (SMC) of the large hemispheres of the rat brain were studied a day after BCO. As shown by microscopy, in intact (pseudo-operated) animals, the cytoarchitectonics of the cerebral cortex was typical (Fig. 1, 2). Different layers of nerve cells were quite clearly traced: molecular, outer granular, outer pyramidal, inner granular, inner pyramidal, and polymorphic. The neuropil had an unstructured appearance. The cells in the layers varied in size, shape, volume of the neuropil, and density.

Vessels of the pia mater of the usual type, capillaries penetrating the brain tissue, mostly with good turgor, plethoric, pericapillary spaces are insignificant. The cell body had a fairly clear, even contour. Neuropil does not have signs of vacuolization. The nucleus of neurons is rounded, predominantly centrally located; the chromatin is uncondensed. The nucleolus is one localized in the center of the nucleus. The glioneuronal index corresponds to the norm for this animal species²¹⁾.

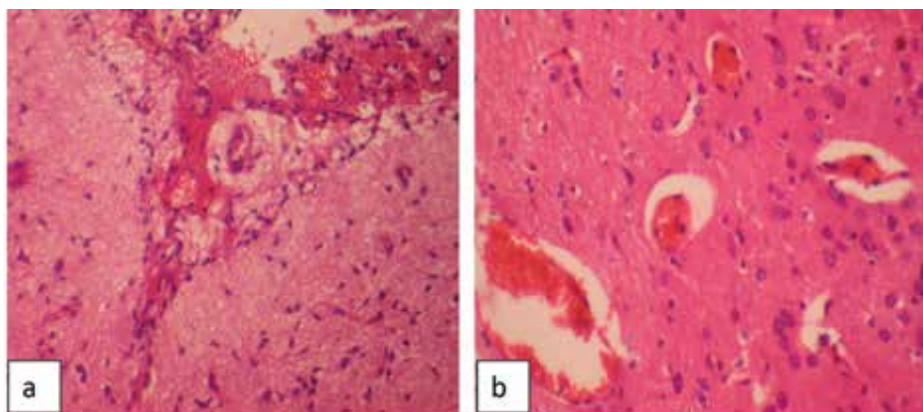


Fig. 3. Area of the cerebral hemisphere of the rat one day after bilateral occlusion of the common carotid arteries: a – hemorrhage in the pia mater; b – plethora of venous vessels (hematoxylin-eosin, $\times 100$)

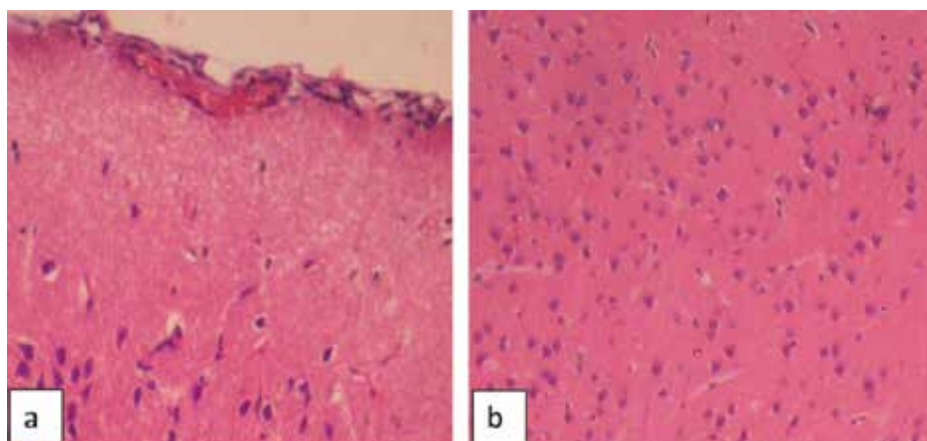


Fig. 4. SMC segment of the cerebral hemisphere of a rat one day after bilateral occlusion of the common carotid arteries against the background of prophylactic administration of raleukin: a – plethora of pia mater vessels; b – normal neuropil density, slight pericellular edema (hematoxylin-eosin, $\times 200$)

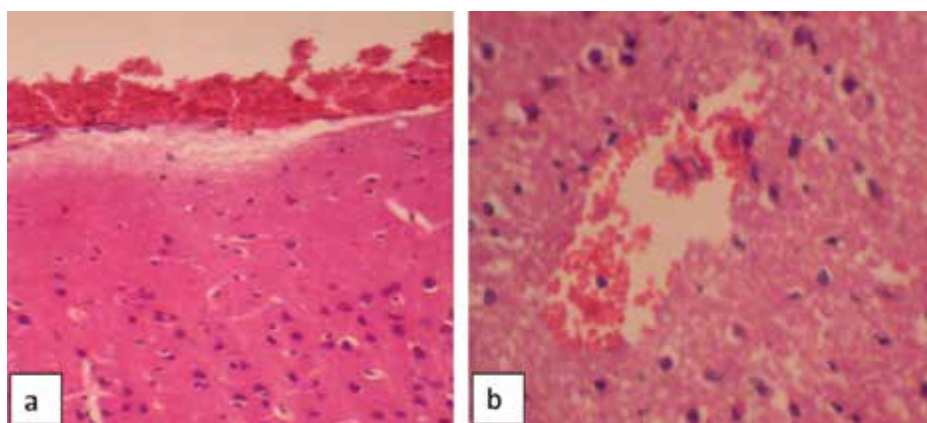


Fig. 5. SMC segment of the rat cerebral hemisphere one day after bilateral occlusion of the common carotid arteries against the background of prophylactic administration of Vinpocetine: a – hemorrhage into the pia mater ($\times 200$); b – hemorrhage in the brain tissue ($\times 250$) (hematoxylin-eosin)

One day after the modeling of ischemic brain injury, pathological changes were observed in the cerebral hemispheres. The vessels of the pia mater are plethoric; in some places, small hemorrhages are visible. Venous vessels are dilated full-blooded (Fig. 3). In the neuropil, there are signs of impaired synaptic patency (the appearance of rarefaction); there are areas with ganglion cell emptying. Some of the capillaries are also full-blooded (sometimes diapedesis of erythrocytes is seen pericapillary); others are in a state of spasm. They pronounced perivascular and pericellular edema. Glioneuronal index significantly increased by 1.3 times.

Prophylactic administration of raleukin to a certain extent prevented the development and severity of pathological changes in rat brains during cerebral ischemia modeling. Hemorrhages into the pia mater or brain tissue were not observed, although the pia mater vessels themselves were plethoric. There were no areas of rarefaction in the neuropil, fewer areas with ganglion cell desolation. Perivascular and pericellular edema were less pronounced (Fig. 4). Perineuronal glial satellitosis was less pronounced, especially the accumulation of glial cells around one neuron. There were no multicellular accumulations of glial cells. The glioneuronal index was significantly lower relative to the control pathology.

In rats that were prophylactically injected with the compared drug vinpocetine, the pia mater was full-blooded in places with hemorrhages; in addition, single small hemorrhages were observed in the brain tissue. There were no disturbances in the state of the neuropil. Signs of vasogenic edema varied (Fig. 5). In satellitosis, the accumulation of glial cells around one neuron quite often took place. The severity of the homotypic arrangement of cells decreased compared to the control pathology. Multicellular accumulations of glial cells were absent. The glioneuronal index decreased compared to the control pathology.

According to morphological features, it can be stated that BCO of the common carotid arteries causes significant reactive changes in the cerebral hemispheres of the rat. A day after the simulation of cerebral ischemia, vasogenic edema of the brain tissue, destruction of varying severity neurons, decreased functional activity, reduced reserve energy and plastic resources of nerve cells, and signs of impaired synaptic conduction were noted. In addition, there was a proliferation of glial elements activation of satellitosis, which, together with an increase in cases of damage and death of nerve cells, also refers to pronounced reactive processes.

Prophylactic administration of raleukin reduces the degree of reactive changes in the SMS of the cerebral hemispheres of rats. It has been established that the number of cells with focal chromatolysis, cytoplasm vacuolization, shadow cells, and neuronophagia signs slightly decrease, and the number of functionally active cells increases. Proliferative manifestations of glial elements and manifestations of vasogenic

edema are also reduced. All of the above indicates that raleukin has cerebroprotective properties. Vinpocetine also moderately reduces the manifestations of reactive processes in the SMC of the cerebral hemispheres of rats after modeling ischemic disorders.

Thus, cerebroprotective raleukin action followed by reperfusion on model BCO starts with cerebral circulation intensification, weakening the ischemic cascade. On condition of irreversible BCO, raleukin contributes to the normalization of cerebral metabolism and performs antiacidotic action, proved by the state of the acid-base balance in blood flowing from the brain. The integral protective effect of raleukin on the ischemic brain shows a decrease in the activity of marker enzyme destruction of neurons by two times – NSE. It extends the concept of neuroprotective action mechanism of IL-1 receptor antagonists.

Conclusion

Recombinant receptor antagonist IL-1 raleukin 15 mg/kg did not affect basal blood flow in the internal carotid artery of intact group animals. Still, it prevents its decrease approximately by three times in case of occlusion of both common carotid arteries followed by reperfusion. Indicators of the cerebroprotective effect of studied medication reduce the acidotic blood shift flowing from the brain of animals with irreversible bilateral carotid occlusion, neuronal degradation, and weakening. Thus interleukin-1 receptor antagonist has cerebroprotective properties. These were obtained by other authors as well^{7, 15, 22}, and they are based on the first proved marker neuronal degradation – neuron enolase. The cerebroprotective properties of raleukin are also confirmed by the data of histopathological studies. It has been proved that the cerebroprotective effect of raleukin is not inferior to the comparison drug vinpocetine in terms of the severity of morphological features.

Conflict of interest: none.

References

1. **Shchokina K. G., Simbirtsev A. S., Ishenko A. M. Shtrygol S., Drogovoz S.** Cerebroprotective properties of interleukin 1 receptor antagonist in models of brain lesions of different genesis. *Cytokines and inflammation* 2012; 1, 52–58.
2. **Helmy A., Guilfoyle M. R., Carpenter K. L., Pickard J. D., Menon D. K., Hutchinson P. J.** Recombinant human interleukin-1 receptor antagonist in severe traumatic brain injury: a phase II randomized control trial. *J. Cereb. Blood. Flow Metab.* 2014; 34(5), 845–851. <https://doi.org/10.1038/jcbfm.2014.23>
3. **Fahey E., Doyle S. L.** IL-1 family cytokine regulation of vascular permeability and angiogenesis. *Front. Immunol.* 2019; 10, 1423. <https://doi.org/10.3389/fimmu.2019.01426>.

4. **Simi A., Tsakiri N., Wang P., Rothwell N. J.** Interleukin-1 and inflammatory neurodegeneration. *Biochem. Soc. Trans.* 2007; 35 (5), 1122–1126. <https://doi.org/10.1042/BST0351122>
5. Patent UA 96037 (51) IPC (2011) A61K 38/20. The use of recombinant antagonist of interleukin-1 receptors (ARIL-1) as an antialcoholic agent / **K. G. Shchokina, S. Y. Shtrigol, O. M. Ischenko**, No u 200912496; appl. 03.12.2009; publ. 26.09.2011.
6. **Greenhalgh A. D., Galea J., Dénes A., Tyrrell P. J., Rothwell N. J.** Rapid brain penetration of interleukin-1 receptor antagonist in rat cerebral ischaemia: pharmacokinetics, distribution, protection. *Br. J. Pharmacol.* 2010; 160, 153–159. <https://doi.org/10.1111/j.1476-5381.2010.00684.x>
7. Patent UA 31373 on utility model IPC (2006) A61K 35/66 The use of an antagonist of interleukin-1 receptors as a means of cerebroprotective action / **Suprun E. V., Shtrigol S. Y., Ischenko O. M., Suprun O. S.** – No u200711672; appl. 22.10.2007; publ. 10.04.2008; Bull. No 7.
8. Patent UA 33402 on utility model IPC (2006) A61K 38/20 The use of an antagonist of interleukin-1 receptors as a means of antihypoxic action / **Suprun E. V., Shtrigol S. Y., Ischenko O. M., Suprun O. S.** – No u200800473; appl. 14.01.2008; publ. 25.06.2008; Bull. No 12.
9. **Banwell V., Sena E. S., Macleod M. R.** Systematic review and stratified meta-analysis of the efficacy of interleukin-1 receptor antagonist in animal models of stroke. *J. Stroke Cerebrovasc. Dis.* 2009; 18(4), 269–276. <https://doi.org/10.1016/j.jstrokecerebrovasdis.2008.11.009>
10. **Xia Y. Y., Song S. W., Min Y., Zhong Y., Sheng Y. C., Li R. P.** The effects of anakinra on focal cerebral ischemic injury in rats. *CNS Neurosci. Ther.* 2014; 20, 879–881. <https://doi.org/10.1111/cns.12310>
11. **Pradillo J. M., Denes A., Greenhalgh A. D.** Delayed administration of interleukin-1 receptor antagonist reduces ischemic brain damage and inflammation in comorbid rats. *J. Cereb. Blood Flow Metab.* 2012; 32(9), 1810–1819. <https://doi.org/10.1038/jcbfm.2012.101>
12. **Mulcahy N. J., Ross J., Rothwell N. J., Loddick S. A.** Delayed administration of interleukin-1 receptor antagonist protects against transient cerebral ischaemia in the rat. *Br. J. Pharmacol.* 2003; 140, 471–476. <https://doi.org/10.1038/sj.bjp.0705462>
13. **Mironov A. N.** Manual on experimental (preclinical) study of new pharmacological substances. Moscow: IIA «Remedium» 2012.
14. **Ghajari M., Hellyer P. J., Sharp D. J.** Computational modelling of traumatic brain injury predicts the location of chronic traumatic encephalopathy pathology. *Brain* 2017; 140 (2), 333–343. <https://doi.org/10.1093/brain/aww317>
15. **Garcia J. H., Liu K. F., Relton J. K.** Interleukin-1 receptor antagonist decreases the number of necrotic neurons in rats with middle cerebral artery occlusion. *Am. J. Pathol.* 1995; 147, 1477–1486.
16. **Haupt W. F., Chopan G., Sobesky J., Liu W. C., Dohmen C.** Prognostic value of somatosensory evoked potentials, neuron-specific enolase, and S100 for short-term outcome in ischemic stroke. *J. Neurophysiol.* 2016; 115, 1273–1278. <https://doi.org/10.1152/jn.01012.2015>
17. **Anand N., Stead L. G.** Neuron-specific enolase as a marker for acute ischemic stroke: a systematic review. *Cerebrovasc. Dis.* 2005; 20(4), 213–219. <https://doi.org/10.1159/000087701>
18. **Basu A., Krady J. K., O'Malley M.** The type 1 interleukin-1 receptor is essential for the efficient activation of microglia and the induction of multiple proinflammatory mediators in response to brain injury. *J. Neurosci.* 2002; 22(14), 6071–6082. <https://doi.org/10.1523/JNEUROSCI.22-14-06071.2002>
19. **Thom J. G., Reeder E. L., Collins S. M., Gopalan P., Robson M. J.** Contributions of interleukin-1 receptor signaling in traumatic brain injury. *Front. Behav. Neurosci.* 2020; 13, 287. <https://doi.org/10.3389/fnbeh.2019.00287>
20. **Loddick S. A., Rothwell N. J.** Neuroprotective effects of human recombinant interleukin-1 receptor antagonist in focal cerebral ischaemia in the rat. *J. Cereb. Blood Flow Metab.* 1996; 16, 932–940. <https://doi.org/10.1097/00004647-199609000-00017>
21. **Belayev L., Alonso O. F., Busto R., Zhao W., Ginsberg, M. D.** Middle cerebral artery occlusion in the rat by intraluminal suture. Neurological and pathological evaluation of an improved model. *Stroke* 1996; 27, 1616–1622. <https://doi.org/10.1161/01.str.27.9.1616>
22. **Lee J. H., Kam E. H., Kim J. M., Kim S. Y., Kim E. J., Cheon S. Y., Koo B. N.** Intranasal Administration of Interleukin-1 Receptor Antagonist in a Transient Focal Cerebral Ischemia Rat. *Model. Biomol. Ther.* (Seoul) 2017; 25(2), 149–157. <https://doi.org/10.4062/biomolther.2016.050>